



Analysis of Movements in Spinal Cord Hemisection Treatment with Amniotic Membrane – Preclinical Study

**M. F. Neves^a, J. L. R. Fonseca^a, P. C. S. Carvalho^a, A. P. C. Pereira^a,
E. H. P. Polisel^a, S. M. P. Pröglhöf^a, L. B. Sant'Anna^a, M. O. Lima^a
and E. A. L. Arisawa^{a*}**

^a Universidade do Vale do Paraíba (UNIVAP), IP&D, Av. Shishima Hifumi, 2911, Urbanova CEP 12244-000, São José dos Campos/SP, Brazil.

Authors' contributions

This work was carried out in collaboration among all authors. Authors LBS, MOL and EALA designed the study, wrote the protocol, and performed the surgical procedures. Authors MFN, JLRF, PCSC, APCP, EHPP and SMPP managed the clinical procedure and functional tests of the study. Authors MFN and JLRF managed the analyses of the study, managed the literature searches, and wrote the first draft of the manuscript. Author MFN performed the statistical analysis. All authors read and approved the final manuscript.

Article Information

DOI: 10.9734/AJOPACS/2022/v10i130148

Open Peer Review History:

This journal follows the Advanced Open Peer Review policy. Identity of the Reviewers, Editor(s) and additional Reviewers, peer review comments, different versions of the manuscript, comments of the editors, etc are available here: <https://www.sdiarticle5.com/review-history/84308>

Original Research Article

Received 12 January 2022

Accepted 16 March 2022

Published 21 March 2022

ABSTRACT

Aims: This study aimed to evaluate the efficacy of Amniotic Membrane application in rats with Spinal Cord Injury induced by transverse hemisection using kinematic analysis and Sciatic Functional Index.

Study design: True experimental research design.

Place and Duration of Study: Instituto de Pesquisa e Desenvolvimento (IP&D) of Universidade do Vale do Paraíba (UNIVAP), between September 2016 and December 2017.

Methodology: Fifteen adult male rats were used, allocated into three equal groups: Control (the spinal cord injury and Amniotic Membrane application were simulated), Lesion (spinal cord injury not treated), Amniotic membrane (spinal cord injury treated by amniotic membrane). All animals underwent surgical procedures. A transverse hemisection was performed in groups Lesion and Amniotic Membrane. A fragment of the biomaterial was applied in group AM covering the

*Corresponding author: E-mail: mirelarisawa@hotmail.com;

hemisection area.

Results: Sciatic Functional Index and motion analysis were performed by comparing images taken at pre- and postoperative time at 7, 14, 21, and 28 days. The kinematic analysis showed a significant difference between groups Control and Lesion at 7 days ($p = 0.023$) and 14 days ($p = 0.015$), and between groups Lesion and Amniotic Membrane at 14 days ($p = 0.039$), comparing the postoperative periods. The Sciatic Functional Index revealed significant differences between Groups Control and Lesion at 7 ($p = -0.002$), 14 ($p = 0.003$), and 21 days ($p = 0.009$), between Groups Control and Amniotic Membrane at 7 ($p = 0.014$), 14 ($p = 0.007$), and 28 days ($p = 0.013$), and between Groups Lesion and Amniotic Membrane only at 14 days ($p = 0.039$).

Conclusion: Application of amniotic membrane in spinal cord hemisection in rats induced gait recovery and improvement in SFI compared to the untreated group.

Keywords: Spinal cord injury; amniotic membrane; kinematic analysis; sciatic functional index.

1. INTRODUCTION

Spinal cord injury (SCI) is defined as damage to the spinal cord, the structure responsible for regulating numerous functions in the body. Depending on the level and degree of SCI, a rapid and devastating loss of neurological functions of the anatomical structures located below the level of injury is observed. Currently, the SCI retrieval process is limited and not very functional [1,2]. The significant increase in the prevalence of spinal cord injuries (SCI) worldwide, associated with the absence of effective treatment protocols, constitutes a public health challenge. Approximate numbers indicate the existence of 2.5 million people with SCI [3,4].

Among the most common causes associated with SCI are automobile accidents, firearm injuries, falls, diving in shallow water or other types of activities and sports, generating an estimated cost over the lifetime of each affected individual, between US\$ 1.1 and US\$ 4.6 million [1, 5].

The impairment of organs responsible for regulating circulatory, respiratory, excretory, sexual, and thermal functions implies damage to the transmission of motor and sensory stimuli between the periphery and the brain [6]. Secondary to this involvement, an intense inflammatory response develops from hours to days after the trauma, followed by axonal demyelination and tissue necrosis. Only after this period is it possible to evaluate the extent of the area injured by SCI and obtain the probable neurofunctional prognosis of the individual [7].

Regenerative medicine has been looking for new therapeutic protocols, including non-steroidal anti-inflammatory drugs, physical therapy, corticosteroid injections, shock wave therapy,

surgery and, currently, the use of biomaterials (BM) and photobiomodulation (PBM) [8-11].

Studies with biomaterials have evaluated the action of amniotic membrane (AM), the inner layer of the placenta, applied for treatment of tissue lesions, since it acts as a “transplanted basal membrane” and as substrate for cell proliferation. This biomaterial has presented positive results due to its biocompatibility and wide availability, and ease of application [12-17].

The microenvironment of AM has numerous growth factors that stimulate cell proliferation and differentiation and has antibacterial and anti-inflammatory actions without the expression of histocompatibility antigens (HLA) [12, 13, 18].

Movement analysis is a non-invasive technique with a high correlation with histological features that allows the evaluation of the efficacy of different treatment protocols by recording kinematic indexes of the animals, monitoring their movements, without damaging the tissues [19]. Therefore, functional indexes, such as the Sciatic Functional Index (SFI), associated with kinematic image analysis, may constitute more reliable evaluations of the functional result of the treatment used without the need for animal euthanasia and histological analysis of the tissues [20].

Considering the above, the present study aimed to evaluate the efficacy of amniotic membrane applied to rats submitted to spinal cord hemisection by the analysis of movements and the Sciatic Functional Index.

2. MATERIALS AND METHODS

This is a true experimental research design approved by the Research Ethics Committee

under the protocol number – 1.647.871 and the Ethics Committee on the Use of Animals under the protocol number A14/CEUA/2014.

2.1 Sample

The sample consisted of 15 adult male rats (*Rattus norvegicus, albinus, Wistar*), weight 230 ± 20 g, 60 days old, housed in polypropylene cages, with a light-dark cycle (12h/12h), controlled temperature of $20 \pm 2^\circ\text{C}$, food (standard chow), and water *ad libitum*. The animals were randomly allocated into three equal groups (n=5): C (Control-simulation of surgical procedures), L (Lesion - spinal cord hemisection), AM (Treated with human amniotic membrane - spinal cord hemisection + AM application).

2.2 Collection and Processing of the AM

The placenta was collected after an elective cesarean section, after the mother's knowledge and consent. The mother should have a gestational age of 37 weeks or more, an uneventful pregnancy, and negative results for HIV-1 and 2, hepatitis B and C, and syphilis. The placenta was processed in the laboratory under sterile conditions and under laminar flow hood. The AM was manually detached from the chorion and washed extensively with physiological solution containing 100U/mL penicillin and 100 μ g/mL streptomycin and amphotericin B. Subsequently, this biomaterial was sectioned into 2 cm² fragments and stored in 50 mL tubes containing DMEM culture medium without the addition of serum and phenol-red at room temperature for no more than 24h [15].

2.2.1 Surgical procedures

After animal hair removal with razor and disinfection of the dorsal region of the rat, tramadol hydrochloride (10 mg/kg, intraperitoneal) was administered for analgesia, followed by anesthesia using 4% isoflurane (inhalation in-camera). Anesthesia was maintained by inhalation of a mixture of oxygen and 1.5% isoflurane during the entire surgical procedure [21]. Next, a 3-cm longitudinal incision was made in the back of the animal in the region between T9-T10. After excision of the spinous processes and exposure of the spinal cord, transverse hemisection was performed in spinal cord with the aid of iris scissors (Fig. 1) in animals from groups L and AM. In the animals of the AM group, an AM fragment was applied, with the mesenchymal side facing the region of the spinal cord lesion, covering the hemisection area. The edges of the membrane were adhered to the surrounding tissues with methacrylate drops (Fig. 2). In the animals of group C, after opening the tissues, the spinal cord injury and the application of the AM fragment were simulated: after excision of the spinous processes and exposure of the spinal cord, no other procedure were performed, and the thoracic incision was closed. The thoracic incision was closed in two layers with 4-0 and 3-0 sutures silk. After the conclusion of the surgical intervention, the animals were housed in individual cages for five days, where they received 5mg/kg of Enrofloxacin 2,5% every 24 hours and 10mg/kg Tramadol Hydrochloride every 12 hours. After this period, the animals were moved to collective cages with up to five animals.

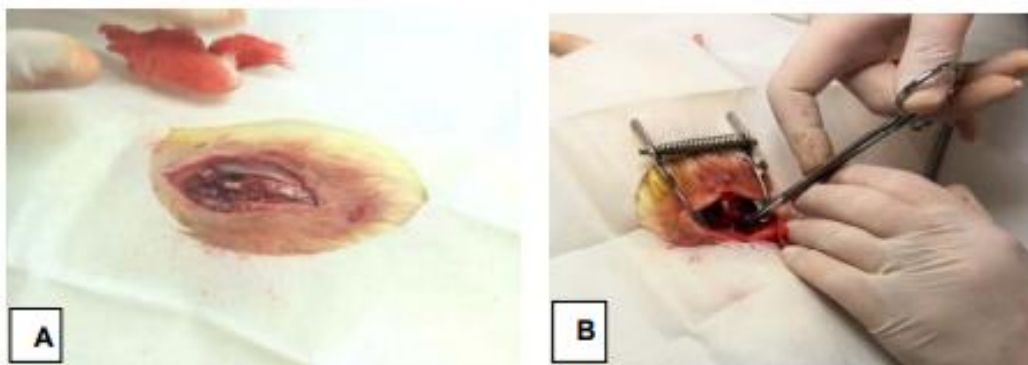


Fig. 1. Surgical procedure for spinal cord injury

(A) Thoracic incisure until spinal cord exposure; (B) Transverse hemi section of spinal cord between T9 and T10 using iris scissors

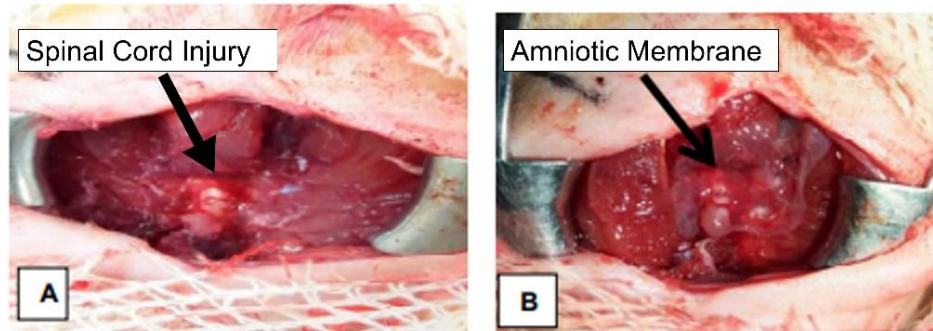


Fig. 2. Surgical procedure for amniotic membrane placement

(A) Exposed spinal cord injury; (B) Application of the AM, with the edges adhered around the region of interest



Fig. 3. Procedures of the Kinematic Analysis

(A) Reflective marker applied to the animal's femur and animal refuge in one end of the glass box used for the analyses; (B) Positioning of the standardized system to capture images of the animals' movements; (C) View of image capture with mobile device positioned at the bottom of the experimental glass box

2.3 Motion Analysis

The Sciatic Functional Index (SFI) and movement analysis were performed by comparing the images captured before and after the surgical procedures. The collections were obtained from a horizontal transparent glass box (118 cm x 10 cm x 18 cm), with a free central area and extremities supported on benches. One the end of the box had a refuge to which the animals moved. To calculate the SFI, images of the movements of the animals were captured by a mobile phone placed in the lower central region of the glass box. For the kinematic analysis we used a system containing two video cameras (Optitrack, model Flex: V100 R2) on tripods located laterally to the area where the movements were collected. A reflective marker was fixed on the femur of the right hind leg of each animal, allowing the capture of animal movements by the camera system. Associating the images of the movements and the displacement time with the help of the Motive

software (OptiTrack[®]), the data were exported in a CVS model and analyzed by the Origin Pro 8.5[®] software (Figs. 3 A, B, and C).

The captured images were imported in "isolated frames" of the gait phases (frames - Microsoft[®] Windows[®] Movie Maker, Version 5.1) and then measured. The frames were saved and exported to the Image J program (Version 1.48, National Institute of Health) for calculation of the parameters PL (length of the experimental footprint), TS (distance between the first and the fifth experimental footbone), and IT (distance between the second and the fourth experimental footbone), referring to the studied times [10].

3. RESULTS

Fig. 4 represents the average gait speed (m/s) calculated by kinematic analysis, and Figure 5 presents the results obtained by the Sciatic Functional Index (SFI), both referring to the

different experimental groups C, L, and AM, in the pre- and postoperative periods, at 7, 14, 21, and 28 days respectively.

In the intragroup analysis of the preoperative and postoperative periods, we could find a significant reduction ($p = 0.01$) of gait mean velocity in the group L between the pre-operative day (0.73 ± 0.10 m/s) and day 14 (0.61 ± 0.06 m/s) (Fig. 4).

In the intergroup analysis, the mean speed of groups C and L (Fig. 4) showed a significant difference compared to the periods of 7 days ($p = 0.003$) and 14 days ($p = 0.02$), and between groups C and AM also in the periods of 7 days ($p = 0.04$) and 14 days ($p = 0.02$). In the other experimental times, the intergroup analyses showed no significant difference ($p > 0.05$).

The analysis of the SFI (Fig. 5) of group C demonstrated the values (-6.24 ± 4.3) preoperatively, showing changes after the simulation of surgical procedures at 7 (-11.41 ± 3.0), 14 (-3.56 ± 14.0), 21 (-7.66 ± 8.4), and 28 days (-7.53 ± 10.2). The data for group L in the preoperative period (-9.42 ± 2.6) were significantly reduced in the postoperative periods at 7 (-56.98 ± 18.1), 14 (-54.87 ± 18.6), and 21 (-51.93 ± 23.0), with a slight improvement at 28 days (-35.45 ± 25.6). Finally, in the AM group, the following values were detected (Fig. 5): preoperatively (-13.65 ± 11.5), and

postoperatively at 7 (-45.16 ± 20.1), 14 (-32.24 ± 8.7), 21 (-27.56 ± 9.3), and 28 days (-7.41 ± 24.5).

Thus, the comparison between the values obtained in groups C, L, and AM in the pre- and postoperative periods (Fig. 5) showed a statistically significant difference between the pre-operative values of group C and L at 7 days ($p = 0.06$), 14 days ($p = 0.01$), and 21 days ($p = 0.04$). The same was observed between the preoperative periods of groups C and AM at 7 days ($p = 0.03$), 14 days ($p = 0.01$), and 21 days ($p = 0.03$), with no significant difference between the preoperative period of group C and the 28-day period for either group L or group AM.

In the intergroup analysis of the SFI (Fig. 5) at 7 days, there was a significant difference between groups C and L ($p = 0.01$) and C and AM ($p = 0.05$), with no difference between groups L and AM on post-operative at day 7. Regarding postoperative day 14, there was a significant difference between all groups: between C and AM ($p = 0.006$) and L and AM (0.01), and between groups C and L, the difference was extremely significant ($p < 0.0001$). On the 21st postoperative day, the difference was significant among all groups, C and L ($p = 0.04$), C and AM ($p = 0.04$), and L and AM ($p = 0.01$). No statistical intergroup difference was observed in the 28-day postoperative period ($p > 0.05$).

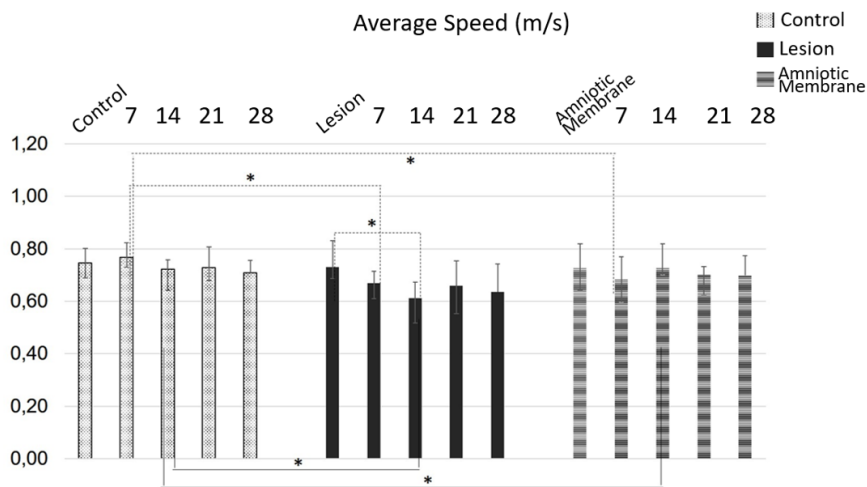


Fig. 4 Kinematic analysis

Mean velocity (m/s) of the groups C, L, and AM in the pre- and postoperative periods at 7, 14, 21, and 28 days
 *Significant difference compared to Control, Lesion, and AM groups (t-test $p < 0.05$)

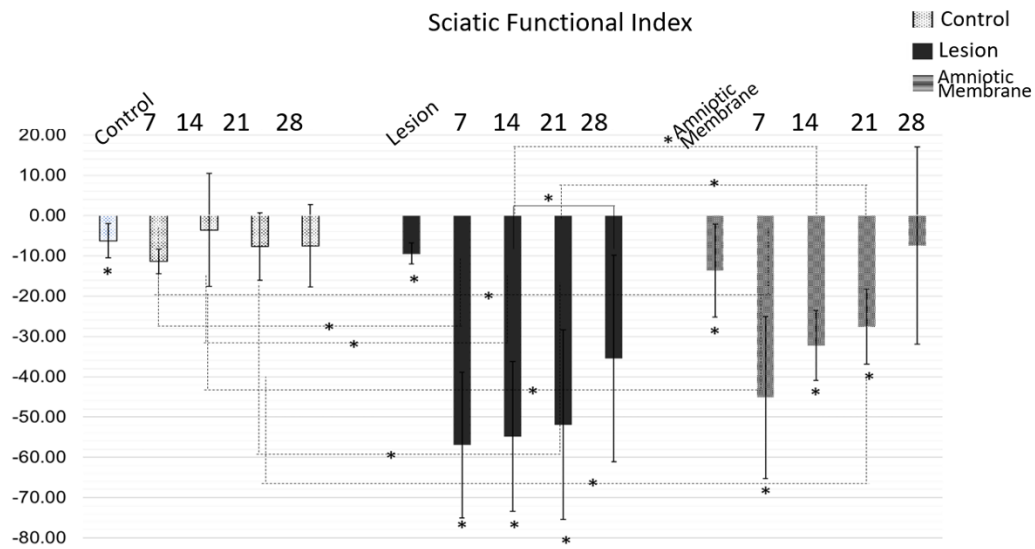


Fig. 5 Sciatic Functional Index for groups C, L, and AM at 7, 14, 21, and 28 days pre- and post-operative periods

* Significant difference compared to Control, Lesion, and AM groups (T-test $p < 0.05$)

In the intragroup analysis of the SFI (Fig. 5), no significant differences were observed in group C between any of the pre- and postoperative periods. In group L, when comparing pre- and post-operative periods, there was a significant difference between pre- and 7th post-operative period ($p = 0.003$), between pre- and 14th post-operative period ($p = 0.004$), and between pre- and 21st post-operative period ($p = 0.01$). In the AM group, significant difference between the preoperative period and the 7th postoperative day ($p = 0.01$), between the preoperative period and the 14th postoperative day ($p = 0.05$), between the preoperative period and the 21st postoperative day ($p = 0.04$), and between the 14th and 28th postoperative days ($p = 0.05$).

4. DISCUSSION

This study aimed to evaluate the efficacy of SCI treatment with the application of AM fragments. The data obtained from kinematic analysis and SFI showed that animals treated with this biomaterial showed less reduction in the indices evaluated in the postoperative period compared to those presented by specimens from group L. Besides being an exhausting treatment, regardless of being a complete or incomplete injury, the long period of treatment and rehabilitation requires patience and motivation

from patients, and, in some cases, family members are included in the rehabilitation [22].

SCI results in a devastating loss of neurological functions affecting all structures below the level of the lesion and can cause significant partial or total loss of body movements and sensations. These consequences are due to the inflammatory process triggered by the trauma, characterized by ischemia and tissue edema, leading to cell death and an intense degenerative process in the nervous tissue [23].

The changes that occur in the tissue microenvironment after SCI impair and hinder the process of axon regeneration, resulting in limited and poorly functioning recovery. SCI is linked to the complete loss of motor and sensory signals, resulting in altered posture and ambulation, and gait recovery is one of the main goals in the rehabilitation of these patients [22, 24].

The search for new and more effective protocols for SCI treatment has triggered the development of new research considering the histopathological, biochemical, and functional alterations identified in the nervous tissue. These new strategies aim to increase the possibilities of controlling the secondary lesion, as well as favoring spinal cord regeneration and neuronal growth [25].

Spinal glia cells contribute to the development of inflammatory and neuropathic response. The neuroinflammatory response after SCI shows that oxaliplatin induction contributes to astrocytes, and astrocyte communicating junctions contribute to elevating hypersensitivity, which showed a significant increase at seven days post-injury [24, 26].

At seven and fourteen days after the injury, both in the analysis of kinematics and SFI, we observed a reduction in the average speed in group L. This result can be explained by the intense inflammatory process caused by the SCI. On the other hand, the similarity in the data collected from groups AM and C is an important result and can be justified by the properties identified in this biomaterial that include the presence of mesenchymal cells, with the broad spectrum of cell differentiation capable of inducing tissue regeneration, and the immunomodulatory and anti-fibrotic actions. The secretion of substance with paracrine action significantly inhibits the inflammatory process in several fibrotic diseases, such as liver cirrhosis, myocardial infarction, lung injury, renal fibrosis, and even in eye surgeries [27, 28].

Spinal cord injury studies with different variables that include the affected anatomical region, intensity of the aggression, depth of the lesion, as well as the secondary inflammatory response allow the definition of its consequences, including progressive tissue loss, presence of edema, hemorrhage, neuronal destruction, and glial cell dysfunction [21]. New treatment protocols proposed for SCI patients include the administration of nonsteroidal anti-inflammatory drugs and/or corticosteroids, shock wave therapy, photobiomodulation, new surgical techniques, and the application of stem cells or biomaterials [21, 24, 29].

Amniotic membrane, or amnion, is the innermost layer of the placenta and is in constant contact with the amniotic fluid. Histologically, the AM is a 0.02 mm to 0.5 mm thick, consisted by a simple cubic epithelium that rests on a thick basal membrane composed of collagen type IV and laminin, and an avascular stromal matrix, rich in collagen types I, III, V, and VI, fibronectin, proteoglycans, glycoproteins, and hyaluronic acid [30], where mesenchymal cells with stem cell potential are observed [31].

In addition, AM contains anti-inflammatory proteins, prostaglandin E₂, and several growth

factors, such as Vascular Endothelial Growth Factor (VEGF), Transforming Growth Factor Beta (TGF- β), Basic Fibroblast Growth Factor (bFGF), Hepatocyte Growth Factor (HGF), and Epidermal Growth Factor (EGF), which stimulate tissue epithelialization and regeneration, without inducing rejection after application, and with mild or no inflammatory response [11,30,32,33].

The great availability and ease of obtaining the AM in the search for a new therapeutic option for individuals with SCI has encouraged this study. The non-invasive analyses performed, which included gait assessment (kinematics) and the Sciatic Functional Index (SFI), allowed for positive and relevant experimental results, encouraging the continuity and expansion of the experimental application of this biomaterial as a treatment protocol for SCI.

The kinematic analysis showed a significant increase in the average speed of the animals in the group AM compared to the animals in group L, suggesting that the evolution in the gait process of the animals treated with AM is associated with the properties attributed to the biomaterial AM [11,12,15,31,32].

Studies already performed by our research group have also demonstrated a great evolution in the gait of animals after the treatment of crush-induced SCI treated with an AM fragment compared to untreated groups [11]. The efficacy of AM application was also confirmed in reconstructive surgeries of the ocular surface [17, 30], in the treatment of liver cirrhosis, with significant reduction of fibrosis severity [15, 31] and in the repair of tendon injuries [18] and even in nervous tissue injuries [34].

According to the tissue engineering, successful tissue regeneration can be accomplished by integrating amniotic membrane in spinal cord injury component as it can provide appropriate ECM, cells and different kinds of growth factor due to these unique and valuable properties. Zhou et al. [35], showed that human amniotic membrane mesenchymal stem cells transplantation promotes neurological functional recovery in rats after traumatic spinal cord injury. Their results indicated that transplanted hAMSCs migrated in the host spinal cord without differentiating into neuronal or glial cells. Compared with the control group, hAMSCs transplantation significantly decreased the numbers of ED1+ macrophages/microglia and caspase-3+ cells. In addition, hAMSCs

transplantation significantly increased the levels of brain-derived neurotrophic factor (BDNF) and vascular endothelial growth factor (VEGF) in the injured spinal cord and promoted both angiogenesis and axonal regeneration. These effects were associated with significantly improved neurobehavioral recovery in the hAMSCs transplantation group. These results show that transplantation of hAMSCs provides neuroprotective effects in rats after SCI, and could be candidate stem cells for the treatment of SCI.

In another animal model study [36] that applied Amniotic membrane over spinal cord injury, which analysed biochemical changes in amniotic membrane treated injured spinal cord using Raman spectroscopy have found no significant changes regarding to biochemical changes in each group besides suggesting changes in lipids and proteins, this possibly indicates efficacy of treatment in a biochemical sense.

5. CONCLUSION

Considering the few studies with the amniotic membrane applied in the treatment of spinal cord injury, the present results show that this biomaterial has great promise in regenerative medicine in this area. The results presented in this unprecedented pre-clinical study, evaluating the mean gait speed and the Sciatic Functional Index in spinal cord hemisection in rats, indicated that the application of the Amniotic Membrane induced recovery and gait improvement compared to the untreated group. Therefore, this preclinical study demonstrated that the application of the amniotic membrane presents itself as an excellent alternative for the treatment of acute spinal cord injury.

DISCLAIMER

The products used for this research are commonly and predominantly use products in our area of research and country. There is absolutely no conflict of interest between the authors and producers of the products because we do not intend to use these products as an avenue for any litigation but for the advancement of knowledge. Also, the research was not funded by the producing company rather it was funded by personal efforts of the authors.

ETHICAL APPROVAL

All authors hereby declare that "Principles of laboratory animal care" (NIH publication No. 85-

23, revised 1985) were followed, as well as specific national laws where applicable. All experiments have been examined and approved by the appropriate ethics committee.

COMPETING INTERESTS

Authors have declared that no competing interests exist.

REFERENCES

1. Ahuja CS, Fehlings M. Concise review: bridging the gap: novel neuroregenerative and neuroprotective strategies in spinal cord injury. *Stem Cells Translational Medicine*. 2016;5(7):914-924.
2. Zhou J, et al. Identification of the spinal expression profile of non-coding RNAs involved in neuropathic pain following spared nerve injury by sequence analysis. *Frontiers in Molecular Neuroscience*. 2017;10:91.
3. Winter B, Pattani H, Temple E. Spinal cord injury. *Anaesthesia & Intensive Care Medicine*. 2017;18(8): 404-409.
4. Kumar R, et al. Traumatic spinal injury: global epidemiology and worldwide volume. *World Neurosurgery*. 2018;113:e345-e363.
5. Ibrahim E, Lynne CM, Brackett NL. Male fertility following spinal cord injury: an update. *Andrology*. 2016;4(1):13-26.
6. James ND, et al. Neuromodulation in the restoration of function after spinal cord injury. *The Lancet Neurology*. 2018;17(10):905-917.
7. Xu Z, et al. Resident Microglia Activate before Peripheral Monocyte Infiltration and p75NTR Blockade Reduces Microglial Activation and Early Brain Injury after Subarachnoid Hemorrhage. *ACS Chemical Neuroscience*. 2018;10(1): 412-423.
8. Zeman RJ, et al. Stereotactic radiosurgery improves locomotor recovery after spinal cord injury in rats. *Neurosurgery*. 2008;63(5):981-988.
9. Wang Y, et al. Melatonin attenuates pain hypersensitivity and decreases astrocyte-mediated spinal neuroinflammation in a rat model of oxaliplatin-induced pain. *Inflammation*. 2017;40(6):2052-2061.
10. Paula AA, et al. Low-intensity laser therapy effect on the recovery of traumatic spinal cord injury. *Lasers in Medical Science*. 2014;29(6):1849-1859.

11. Arisawa EAL, et al. Amniotic Membrane in the Treatment of Spinal Cord Injuries. *Injury*. 2017;161:217-233.
12. Manuelpillai U, et al. Amniotic membrane and amniotic cells: potential therapeutic tools to combat tissue inflammation and fibrosis? *Placenta*. 2011;32: S320-S325.
13. Starecki M, Schwartz JA, Grande DA. Evaluation of amniotic-derived membrane biomaterial as an adjunct for repair of critical sized bone defects. *Advances In Orthopedic Surgery*; 2014.
14. Ullah I, Subbarao RB, Rho GJ. Human mesenchymal stem cells-current trends and future prospective. *Bioscience Reports*. 2015;35(2):e00191.
15. Sant'anna LB, et al. Amniotic membrane application reduces liver fibrosis in a bile duct ligation rat model. *Cell Transplantation*. 2011;20(3):441-453.
16. Loukogeorgakis SP, De Coppi P. Concise review: amniotic fluid stem cells: the known, the unknown, and potential regenerative medicine applications. *Stem Cells*. 2017;35(7):1663-1673.
17. Shoaib KK, Shakoor T, Amin MS. Presentation and Surgical Management of Epibulbar (Limbal) Dermoids. *Pakistan Journal of Ophthalmology*. 2018;34(3): 1663-1673.
18. Nicodemo MC, et al. Amniotic membrane as an option for treatment of acute Achilles tendon injury in rats. *Acta Cirurgica Brasileira*. 2017;32(2):125-139.
19. Oliveira EF, Mazzer N, Barbieri CH, Selli M. Correlation between functional index and morphometry to evaluate recovery of the rat sciatic nerve following crush injury: experimental study. *J Reconstr Microsurg*. 2011;17(1):69–75.
20. Varejão ASP, Meek MF, Ferreira AJA, Patrício JAB, Cabrita AMS. Functional evaluation of peripheral nerve regeneration in the rat: walking track analysis. *J Neurosci Methods*. 2001;108:1–9.
21. Paula AA, et al. Low-intensity laser therapy effect on the recovery of traumatic spinal cord injury. *Lasers In Medical Science*. 2014;29(6):1849-1859.
22. Nas K, et al. Rehabilitation of spinal cord injuries. *World journal of orthopedics*. 2015;6(1):8.
23. Ahuja CS, et al. Traumatic spinal cord injury. *Nature Reviews Disease Primers*. 2017;3(1):1-21.
24. Wang M, et al. Bioengineered scaffolds for spinal cord repair. *Tissue Engineering Part B: Reviews*. 2011;17(3):177-194.
25. Rouanet C, et al. Traumatic spinal cord injury: current concepts and treatment update. *Arquivos de Neuro-Psiquiatria*. 2017;75(6):387-393.
26. Yoon SY, et al. Spinal astrocyte gap junctions contribute to oxaliplatin-induced mechanical hypersensitivity. *The Journal of Pain*. 2013;14(2):205-214.
27. Kim SJ, et al. Anti-inflammatory effect of tauroursodeoxycholic acid in RAW 264.7 macrophages, bone marrow-derived macrophages, BV2 microglial cells, and spinal cord injury. *Scientific Reports*. 2018;8(1):1-11.
28. Navas A, et al. Anti-inflammatory and anti-fibrotic effects of human amniotic membrane mesenchymal stem cells and their potential in corneal repair. *Stem Cells Translational Medicine*. 2018;7(12):906-917.
29. Goel A. Stem cell therapy in spinal cord injury: Hollow promise or promising science? *Journal of Craniovertebral Junction & Spine*. 2016;7(2):121.
30. Jirsova K, Jones GLA. Amniotic membrane in ophthalmology: properties, preparation, storage and indications for grafting—a review. *Cell and Tissue Banking*. 2017;18(2):193-204.
31. Sant'anna LB, Hage R, Cardoso MAG, Arisawa EAL, Cruz MM, Parolini O, et al. Antifibrotic Effects of Human Amniotic Membrane Transplantation in Established Biliary Fibrosis Induced in Rats. *Cell Transplant*. 2016;25(12):2245-57.
32. Sane, MS, et al. Biochemical characterization of pure dehydrated binate amniotic membrane: role of cytokines in the spotlight. *Regenerative Medicine*. 2018;13(6):689-703.
33. Özbölük Ş, et al. The effects of human amniotic membrane and periosteal autograft on tendon healing: experimental study in rabbits. *Journal of Hand Surgery (European Volume)*. 2010;35(4):262-268.
34. Shaw KA, et al. The Science and Clinical Applications of Placental Tissues in Spine Surgery. *Global Spine Journal*. 2018;8(6):629–637.
35. Zhou HL, Zhang XJ, Zhang MY, et al. Transplantation of Human Amniotic Mesenchymal Stem Cells Promotes Functional Recovery in a Rat Model of

- Traumatic Spinal Cord Injury. *Neurochem Res.* 2016;41:2708–2718.
36. Coutinho EST, et al. Raman spectroscopy of healthy, injured and amniotic membrane treated rat spinal cords. *Spectrochimica Acta Part A: Molecular and Biomolecular Spectroscopy.* 2022;265:120323.

© 2022 Neves et al.; This is an Open Access article distributed under the terms of the Creative Commons Attribution License (<http://creativecommons.org/licenses/by/4.0>), which permits unrestricted use, distribution, and reproduction in any medium, provided the original work is properly cited.

Peer-review history:

The peer review history for this paper can be accessed here:
<https://www.sdiarticle5.com/review-history/84308>